

# Localization of proliferating cell nuclear antigen-immunoreactivity in human dental pulp and gingiva

A. CASASCO\*, M. CASASCO\*, A. CALLIGARO\*, M. REGUZZONI\*, G. MARRONE\*\* and E. ROMEO\*\*

\* *Institute of Histology & Embryology, University of Pavia, via Forlanini 10, 27100 Pavia (Italy).*

\*\* *Dental Clinic, Hospital «S. Paolo», University of Milan, via di Rudinì 8, 20142 Milano (Italy).*

## SUMMARY

The proliferating cell nuclear antigen (PCNA) is regarded as an operational marker of proliferating cells. We have used PC10 monoclonal antibody to PCNA to reveal proliferation sites in human dental pulp and gingiva. Intense PCNA-immunoreactivity was observed in the basal layer of the gingiva lining epithelium and within some cells of the underlying connective tissues, including some endothelial and perivascular cells. PCNA-reactive cells were scattered throughout the pulp tissue, but were particularly numerous in the peripheral part. Since PCNA is an endogenous cell cycle-related molecule, we propose that PCNA-antibodies may represent useful tools for studying cell kinetics in human oral tissues in normal as well as pathological situations, such as tumors, wound healing and inflammation.

## KEY WORDS:

Proliferating cell nuclear antigen - Dental pulp - Gingiva - Proliferation - Human.

## RÉSUMÉ

L'antigène nucléaire de la prolifération cellulaire (PCNA) est considéré comme un marqueur de la prolifération cellulaire. Nous avons utilisé l'anticorps monoclonal PC10 pour le PCNA afin de mettre en évidence les sites de prolifération dans la pulpe dentaire humaine et dans la gencive. Une immunoréactivité intense pour le PCNA a été observée au niveau de la couche basale de l'épithélium gingival et dans certaines cellules du conjonctif sous-jacent, comprenant des cellules endothéliales et des cellules perivasculaires. Les cellules PCNA-réactives sont dispersées dans la pulpe, mais sont particulièrement nombreuses dans les portions de la périphérie. Etant donné que le PCNA est une molécule endogène en liaison avec le cycle cellulaire, nous proposons que les anticorps antiPCNA peuvent constituer un excellent moyen pour étudier les cinétiques cellulaires dans les tissus oraux humains aussi bien dans des situations normales que pathologiques telles que tumeurs, cicatrisation des plaies et inflammation.

## MOTS CLEFS:

PCNA - Pulpe dentaire - Gencive - Prolifération - Humain.

## INTRODUCTION

Cell kinetic studies provide useful informations about the biology of normal as well as pathological tissues, such as tumors or hyperplastic lesions. The development of monoclonal antibodies to cell cycle-related molecules provides the basis for the immunocytochemical detection of replicating cells in tissues. The proliferating cell nuclear antigen (PCNA) is an auxiliary molecule to DNA polymerase delta, an enzyme involved in the DNA replication machinery (Celis *et al.*, 1984; Celis and Celis, 1985; Kurki *et al.*, 1986; Bravo and Macdonald-Bravo, 1987). Previous studies have demonstrated that PC10 monoclonal antibody to PCNA is a suitable reagent to reveal G1-, S- and G2/M-phases traversing cells, i.e. cycling cells, in tissues (Hall *et al.*, 1990; Casasco *et al.*, 1993). Accordingly, PC10 antibody has been recently used to study cell proliferation in human and rat tooth germs by immunocytochemistry and flow-cytometry (Christensen *et al.*, 1993; Casasco *et al.*, 1995).

Our aim was now to study distribution of PCNA-immunoreactive cells in human dental and periodontal tissues using immunocytochemistry.

## MATERIALS AND METHODS

Samples of human dental pulp ( $n=10$ ) were obtained from healthy impacted third molars extracted for orthodontic purposes. Samples of healthy human gingiva from the region of the third molars ( $n=10$ ) were obtained from volunteers during surgical procedures to remove impacted teeth. The samples of dental pulp and gingiva were processed according the protocol that was found to be optimal to preserve PCNA-immunoreactivity (Casasco *et al.*, 1993, 1994). Briefly, the samples were immediately immersed for 6 hours in methacarn (a modified Carnoy's fixative solution of 60% absolute methanol, 30% chloroform and 10% glacial acetic acid), dehydrated in graded methanols and routinely embedded in paraffin. The samples were cut at 8-10  $\mu\text{m}$  and rehydrated sections were stained for the immunocytochemical detection of PCNA using an indirect immunoperoxidase technique. Sections were incubated serially with the following solutions: 1) 0.3% hydrogen peroxide for 30 min; 2) normal goat serum, diluted 1:20, for 30 min; 3) monoclonal antibody to PCNA, clone PC10, a mouse IgG2a (Dako, Glostrup, Denmark) diluted 1:400, overnight

at 4°C; 4) biotinylated goat anti-mouse IgG, diluted 1:100, for 1 h at room temperature; 5) streptavidin-biotinylated peroxidase complexes, diluted 1:200, at room temperature for 1 h each step; 6) 0.03% 3,3'-diaminobenzidine tetrahydrochloride solution to which hydrogen peroxide (0.02%) was added just before use. Each solution was prepared in 0.05 M Tris buffer, pH 7.4, containing 0.1 M NaCl (0.15 M Tris buffer saline, TBS) and between each step of the immunostaining procedure the sections were washed in the same buffer.

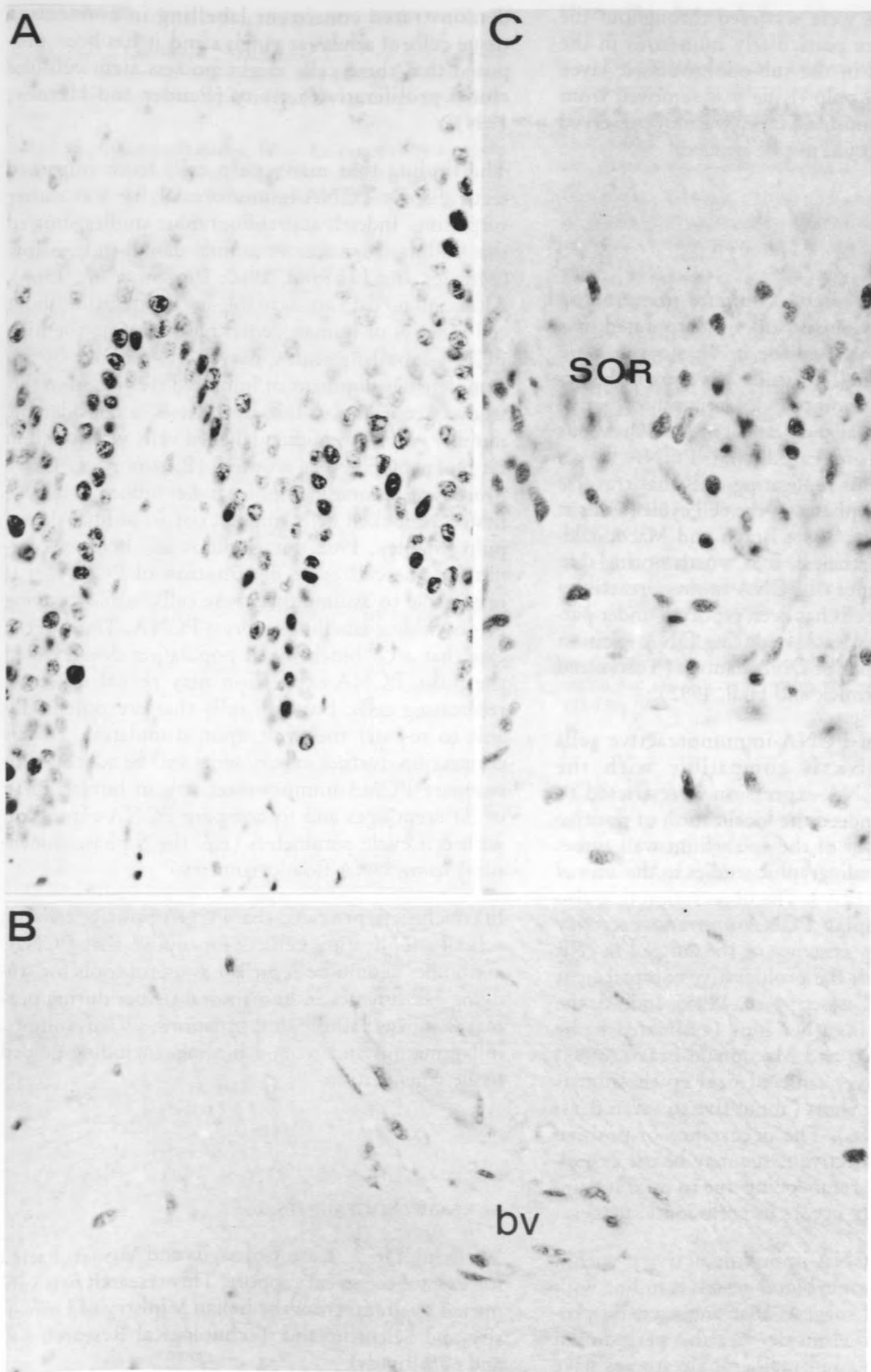
PC10 monoclonal antibody has been previously characterized (Hall *et al.*, 1990; Waseem and Lane, 1990). Specificity controls included: 1) omission of the primary antibody; 2) substitution of the primary antibodies with non-immune sera or monoclonal antibodies from the same immunoglobulin subclass.

## RESULTS

Specific immunoreaction was restricted to the nucleus of positive cells (Fig. 1A,B,C). In the gingiva, intense immunostaining was observed within the basal and suprabasal cells of the lining epithelium, within some cells of the underlying connective tissue and within some endothelial cells (Fig. 1A,B).

Fig. 1: Immunocytochemical detection of proliferating cell nuclear antigen-immunoreactivity in human gingiva (A,B) and dental pulp (C). The reaction is visible in the nuclei of positive cells. In the gingiva, positive cells are detectable in the basal layers of the lining epithelium and in the underlying connective tissue (A). Gingival vascular endothelium is occasionally stained (B). In the dental pulp, immunoreactive cells are scattered throughout the tissue, being particularly numerous in the peripheral part, i.e. the sub-odontoblastic region (C). SOR, sub-odontoblastic region. bv, blood vessel. Indirect immunoperoxidase technique.  $\times 400$ .

Fig. 1: Détection immunocytochimique de l'antigène nucléaire de la prolifération cellulaire dans la gencive humaine (A, B) et la pulpe dentaire (C). La réaction est visible au niveau des noyaux des cellules positives. Dans la gencive, des cellules positives sont détectées dans les couches basales de l'épithélium de revêtement et dans le conjonctif sous-jacent (A). L'endothélium des vaisseaux gingivaux est coloré occasionnellement. Dans la pulpe dentaire, les cellules immunoréactives sont dispersées dans le tissu, tout en étant particulièrement nombreuses en périphérie, c'est-à-dire dans la région sous-odontoblastique (C). SOR, région sous-odontoblastique, bv, vaisseau sanguin. Technique immunoperoxydase indirecte.  $\times 400$ .



PCNA-reactive cells were scattered throughout the pulp tissue, but were particularly numerous in the peripheral part and in the sub-odontoblastic layer (Fig. 1C). Since the pulp tissue was removed from the dentine, the odontoblast layer was not preserved in the samples and could not be studied.

## DISCUSSION

Classical autoradiographic techniques that employ exogenous radioactive nucleotides incorporated into the DNA can not be used for *in vivo* cytokinetic studies in the human. This study has shown the occurrence and distribution of PCNA-immunoreactive cells in human dental pulp and gingiva. Previous studies have demonstrated that PCNA is an endogenous marker of replicating cells that traverse the G1, S and G2/M phases of the cell cycle (Celis *et al.*, 1985; Kurki *et al.*, 1986; Bravo and Macdonald-Bravo, 1987). Nevertheless, it is worth noting that the possible occurrence of PCNA-immunoreactivity within non-cycling cells has been reported under particular circumstances, such as during DNA excision repair as a consequence of DNA damage (Toschi and Bravo, 1988; McCormick and Hall, 1992).

The distribution of PCNA-immunoreactive cells observed in gingiva is compatible with the hypothesis that PCNA-expression is restricted to proliferating cells. Indeed the localization of positive cells in the basal layer of the epithelium well agrees with previous autoradiographic studies in the animal (Hume and Potten, 1979). The observation that also suprabasal cells display PCNA-immunoreactivity may be due to the persistence of the antigen in cells that have recently left the proliferative compartment (Scott *et al.*, 1991; Casasco *et al.*, 1995). Indeed, the half-life of PCNA is rather long (estimated to be about 20 h by Bravo and Macdonald-Bravo, 1987) whereas the turnover time of oral epithelium is estimated to be very short (about five to seven days; Andersen *et al.*, 1986). The occurrence of positive cells in gingival connective tissue may be the expression of partial tissue remodelling due to mild inflammation that naturally occurs in periodontal tissues.

The presence of PCNA-immunoreactivity within endothelial cells of some blood vessels is in line with this hypothesis and suggests that angiogenetic processes may occur in clinically healthy periodontal tissues. Interestingly, autoradiographic studies have

demonstrated consistent labelling in connective tissue cells of adult rat gingiva and it has been proposed that these cells might possess stem cell-like clonal proliferative activity (Pender and Heaney, 1994).

The finding that many pulp cells from impacted teeth display PCNA-immunoreactivity was rather surprising. Indeed, autoradiographic studies showed that cellular turnover in animal dental pulp is low (Messier and Leblond, 1960; Pinzon *et al.*, 1966). Although no data are available in the literature about cell kinetics of human dental pulp *in vivo*, the high PCNA-labelling index may be explained by incomplete development of impacted teeth used in this study. According to this hypothesis, a considerable number of H<sup>3</sup>-thymidine labelled cells was found in rat molar pulp before eruption (Pinzon *et al.*, 1966). Moreover, autoradiographic studies induce to believe that G2-blocked cells might exist in animal dental pulp (Stanley, 1962; Fitzgerald *et al.*, 1990). According to the cell cycle distribution of PCNA, it is reasonable to assume that these cells, while escaping H<sup>3</sup>-thymidine-labelling, express PCNA. Thus, in the case that a G2-blocked cell population does exist in the pulp, PCNA-expression may reveal not only replicating cells, but also cells that are potentially able to re-enter the cycle upon stimulation. In this connection, further experiments will be addressed to compare PCNA-immunoreactivity in human teeth of different ages and to compare PCNA-expression with cell cycle parameters (e.g. the S phase dimension) using DNA flow cytometry.

In conclusion, provided that PCNA-positive cells are actually replicating cells, we propose that PCNA-antibodies should be regarded as useful tools for studying cell kinetics in human oral tissues during normal as well as pathological situations, such as tumors, inflammation and wound healing, including guided tissue regeneration.

## ACKNOWLEDGEMENTS

We thank Dr. A. Icaro Cornaglia and Mrs. A. Farina for helpful technical support. This research was supported by grants from the Italian Ministry of University and Scientific and Technological Research (40 and 60% funds).

## REFERENCES

- Andersen, L., Karring, T., Mackenzie, I. — Oral mucous membrane. In *Human oral Embryology and Histology* (Eds. Mjor, I.A. and Fejerskov, O.), pp. 203-242, Munksgaard, Copenhagen, 1986.
- Bravo, R., Macdonald-Bravo, H. — Existence of two populations of cyclin-proliferating cell nuclear antigen during the cell cycle: association with DNA replication sites. *J. Cell Biol.*, 105: 1549-1554, 1987.
- Casasco, A., Giordano, M., Danova, M., Casasco, M., Icaro Cornaglia, A., Calligaro, A. — PC10 monoclonal antibody to proliferating cell nuclear antigen as probe for cycling cell detection in developing tissues. *Histochemistry*, 99: 191-199, 1993.
- Casasco, A., Casasco, M., Icaro Cornaglia, A., Danova, M., Giordano, M., Calligaro, A. — Tissue fixation for immunohistochemical detection of proliferating cell nuclear antigen with PC10 monoclonal antibody. *Biotech. Histochem.*, 69: 112-117, 1994.
- Casasco, A., Casasco, M., Icaro Cornaglia, A., Mazzini, G., De Renzis, R., Tateo, S. — Detection of bromo-deoxyuridine and proliferating cell nuclear antigen-immunoreactivities in tooth germ. *Conn. Tiss. Res.*, 32: 63-70, 1995.
- Celis, J.E., Bravo, R., Larsen, P.M., Fey, S.J. — Cyclin: a nuclear protein whose level correlates directly with the proliferative state of normal as well as transformed cells. *Leukemia Res.*, 8: 143-157, 1984.
- Celis, J.E., Celis, A. — Cell cycle-dependent variations in the distribution of the nuclear protein cyclin proliferating cell nuclear antigen in cultured cells: subdivision of S phase. *Proc. natn. Acad. Sci. U.S.A.*, 82: 3262-3266, 1985.
- Christensen, L.R., Mollgard, K., Kjaer, I., Stagaard Janas, M. — Immunocytochemical demonstration of nerve growth factor receptor (NGF-R) in developing human fetal teeth. *Anat. Embryol.*, 188: 247-255, 1993.
- Fitzgerald, M., Chiego jr., D.J., Heys, D.R. — Autoradiographic analysis of odontoblast replacement following pulp exposure in primate teeth. *Archs oral Biol.*, 35: 707-715, 1990.
- Hall, P.A., Levinson, D.A., Yu, C.C.W., Woods, A.L., Kellock, D.B., Watkins, J.A. — Proliferating cell nuclear antigen (PCNA) immunolocalization in paraffin sections: an index of cell proliferation with evidence of deregulated expression in some neoplasms. *J. Pathol.*, 162: 285-294, 1990.
- Hume, W.J., Potten, C.S. — Advances in epithelial kinetics — an oral view. *J. oral pathol.*, 8: 3-22, 1979.
- Kurki, P., Vanderlaan, M., Dolbeare, F., Gray, J., Tan, E.M. — Expression of proliferating cell nuclear antigen (PCNA) cyclin during the cell cycle. *Exp. Cell Res.*, 166: 209-219, 1986.
- McCormick, D., Hall, P.A. — The complexities of proliferating cell nuclear antigen. *Histopathology*, 21: 591-594, 1992.
- Messier, B., Leblond, C.P. — Cell proliferation and migration as revealed by radioautography after injection of thymidine- $H^3$  into male rats and mice. *Am. J. Anat.*, 106: 247-285, 1960.
- Pender, N., Heaney, T.G. — Cell generation within interdental gingival septum of the rat. *J. Periodont. Res.*, 29: 17-24, 1994.
- Pinzon, R.D., Toto, P.D., O'Malley, J. — Kinetics of rat molar pulp cells at various ages. *J. dent. Res.*, 45: 934-939, 1966.
- Scott, R.J., Hall, P.A., Haldane, J.S., Van Noorden, S., Price, Y., Lane, D.P., Wright, N.A. — A comparison of immunohistochemical markers of cell proliferation with experimentally determined growth fraction. *J. Pathol.*, 165: 173-178, 1991.
- Stanley, H.R. — The cells of the dental pulp. *Oral Surg.*, 15: 849-858, 1962.
- Toschi, L., Bravo, R. — Changes in cyclin/proliferating cell nuclear antigen distribution during DNA repair synthesis. *J. Cell Biol.*, 107: 1623-1628, 1988.
- Waseem, N.H., Lane, D.P. — Monoclonal antibody analysis of the proliferating cell nuclear antigen (PCNA). Structural conservation and the detection of the nucleolar form. *J. Cell Sci.*, 96: 121-129, 1990.

## Address for correspondence:

Prof. A. Casasco  
 Institute of Histology & Embryology,  
 University of Pavia,  
 via Forlanini 10, Pavia (Italy)  
 Tel.: 382-507272  
 Facsimile: 382-528330.