

SHORT COMMUNICATION

O-14. EVALUATION OF THE NEWLY FORMED BONE IN IRRADIATED AREAS BY ADDITION OF MESENCHYMAL STEM CELLS TO THE ASSOCIATION OF BIPHASIC CALCIUM PHOSPHATE AND TOTAL BONE MARROW

P. Bléry^{1,4}, F. Espitalier^{1,2}, P. Corre^{1,3}, S. Sourice¹, P. Pilet¹, Y. Amouriq^{1,4}, J. Guicheux¹, P. Weiss¹, O. Malard^{1,2}

¹INSERM, UMRS 791, laboratoire d'ingénierie ostéo-articulaire et dentaire, LIOAD, 1 Place Alexis Ricordeau, F44042 Nantes Cedex, France ²Service d'ORL et de chirurgie cervico-faciale, 1 place Alexis Ricordeau, CHU Hôtel Dieu, 44042 Nantes Cedex 1, France ³Service de stomatologie et de chirurgie maxillo-faciale, 1 place Alexis Ricordeau, CHU Hôtel Dieu, 44042 Nantes Cedex 1, France ⁴Faculté de chirurgie dentaire, Université de Nantes, 1 Place Alexis Ricordeau, F44042 Nantes Cedex, France

Key words

bone repair, tissue engineering, radiation, neovascularization, biomaterial

Introduction

The treatment of the squamous cell carcinomas of the upper aerodigestive tract requires large therapeutic surgical bone removal in association with external radiation therapy. The consequences are esthetic and above all functional. The standard surgical treatment of reconstruction is the use of micro-anastomosed free-flaps or autogenous bone graft. But these techniques are seldom performed because of the risk of surgical complications in irradiated areas, of prolonged general anesthesia, and the reduction of healing capacities of the irradiated bone. So tissue engineering using calcium phosphate biomaterials is considered a good alternative. In irradiated areas, the association of BCP and TBM provides better bone reconstruction than BCP or TBM alone [1,2,3]. And the association of BCP and MSC doesn't increase the bone reconstruction, due to the cellular and vascular poorness of the bone marrow and the irradiated bone [3]. The aim of the study is to determine if the association of BCP+TBM+MSC promotes the bone reconstruction in irradiated areas. This study is an in vivo animal study and is based on the comparison of the new bone formation after implantation of four filling materials.

Materials and methods

The study will be performed on thirty inbred Lewis 1A rats, eight weeks of age, twenty four females, and six males designated as cell graft donors. The MSC will be sampled for three non-irradiated male donors and put in culture for proliferation and differentiation. The twenty four females will be irradiated at day zero, by a single dose of 20 grays. Three weeks after, critical size defects (3mm) will be created on the femurs and tibias of the females and the osseous defects will be filled with BCP, BCP+TBM, BCP+TBM+ non-differentiated MSC, or BCP+TBM+ differentiated MSC. The sampling of TBM of the three non-irradiated male donors will be taken at the same time as the surgery. Three weeks after implantations, implanted bone defects will be removed just after euthanasia and the non-decalcified bone specimens will be infiltrated and embedded in a glycol methacrylate resin for qualitative and quantitative analysis.

Results

Histological examination

New-bone formation was greater after BCP-TBM mixture implantation than with the other filling materials. Newly formed bone was observed at the periphery of most of the osseous defects. Following BCP-TBM mixture implantation, new-bone formation was also observed towards the centre of the defect. Many


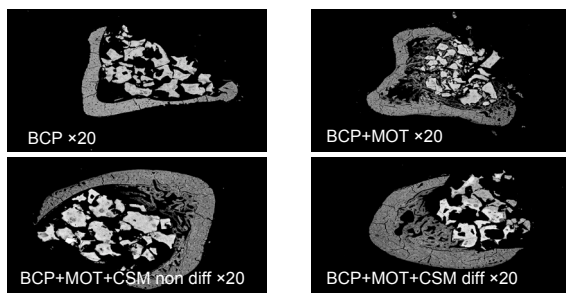
newly formed blood vessels were observed in the defects filled with the BCP–TBM mixture.

SEM and image analysis

New-bone formation was most dense after BCP–TBM mixture implantation, at the periphery and towards the centre of the osseous defects. After implantation of BCP–TBM-MSCs mixtures or BCP alone, only rare bone formations were observed at the periphery of the osseous defects.

The rate of bone ingrowth was significantly higher after implantation of the BCP-TBM mixture than after BCP alone, and BCP-TBM-MSC differentiated or not.

0251659264000251659264



Discussion

The association of BCP+TBM+MSC doesn't increase the new bone formation. It's possible to propose some hypotheses: a competition between the TBM cells and the MSC; a higher number of implanted cells which dilute the TBM cells; and the anti-inflammatory role of the MSC could be higher than the osteoprogenitor one.

Conclusion

The association of BCP+TBM+MSC doesn't increase the new bone formation. The association BCP-TBM is the most efficient material for bone substitution in irradiated areas. The BCP–TBM mixture may induce the angiogenesis of repair tissue and thus balance the side-effects of irradiation. On the other hand, the precise role of angiogenesis and hematopoietic cells in bone repair should be ascertained by further investigations.

Acknowledgments

This work was supported by grants from "la ligue contre le cancer" foundation. We thank Biomatlante (Vigneux de Bretagne, France) for supplying materials.

References

1. Lerouxel E. et al. (2006) *Biomaterials*; 27(26):4566-4572.
2. Malard O. et al. (2005) *Key Engineering Materials*; 284-286:285-288.
3. Espitalier F. et al. (2009) *Biomaterials*; 30(5):763-769 (1):37-42