

## POSTERS

### **P2 - A COMBINATION OF ZYGOMATIC FIXTURES , AUTOGRAFT, ALLOGRAFT AND PRP (PLATELET-RICH-PLASMA ) ALLOWS A FIXED PROSTHETIC REHABILITATION OF THE MAXILLA, IN CASE OF SEVERE POST-TRAUMATIC BONE LOSS**

**L. Evrard, R. Glineur**

Service de stomatologie et de Chirurgie Maxillo-faciale, Hôpital Erasme – ULB- Bruxelles - Belgium  
levrard@ulb.ac.be

#### **KEY WORDS**

Zygomatic implants, PRP, PRF, bone graft

#### **INTRODUCTION**

For the maxilla, in case of a post-traumatic loss or of a major post-edentation resorption, functional and esthetic rehabilitation with a fixed prosthesis can be achieved by means of two or four zygomatic fixtures plus two to four conventional implants in the anterior region. In these cases, a reconstruction of the anterior part of the maxilla can be performed, using a bone autograft completed with an allograft and autologous platelet concentrates Platelet-Rich Plasma (PRP) which have been shown to enhance the maturation rate of bone, bone density, as well as to accelerate resorption of some biomaterials particules. The large number of platelets they contain release significant quantities of growth factors ( PDGF-aa, PDGF-ab, PDGF-bb, TGF- $\beta$ 1, TGF-  $\beta$ 2, VEGF, EGF), which promote neovascularization and osseous regeneration, by the way of mitogenic and chemotactic effects on mesenchymal Stem Cells, pre-osteoblastic and osteoblastic cells . The cell adhesion molecules they contain (fibrine, fibronectin, vitronectin) act as a matrix for bone regeneration and play a role in osteoconduction.

Platelet concentrates are used in the form of gel and/or membranes, and are easy to apply in clinical practice. They offer potential benefits including rapid wound healing and bone regeneration, enhanced bone graft density and maturation, and accelerated resorption of biomaterial particules.

#### **METHODS AND MATERIALS**

A clinical case is presented, involving placement of two zygomatic fixtures, in conjunction with a cranial autograft, completed by use of particulated Freeze Dried Bone Allograft (FDBA) and Platelet-Rich Plasma (PRP) in the form of gel and membranes.

Biopsies were taken 5 months after bone grafting, at the time of implant placement in the region of the anterior maxilla. Histological analysis was performed, in order to evaluate the effects of PRP on bone maturation and bone density, in the case of the use of a bone autograft in conjunction with an allograft .

#### **RESULTS**

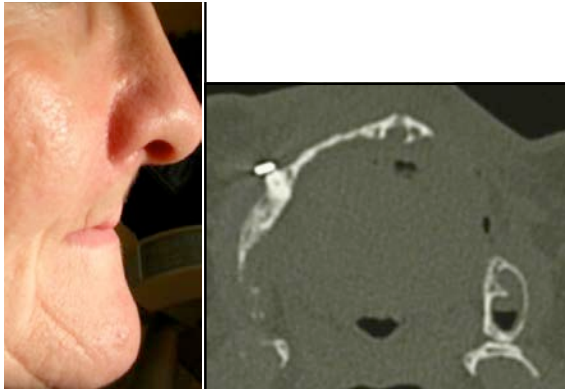
Histological sections show the very good degree of maturation of the reconstructed bone (lamellar bone, poor cellularity, absence of inflammatory infiltrate). X-rays show the level of bone around implants

#### **CONCLUSION**

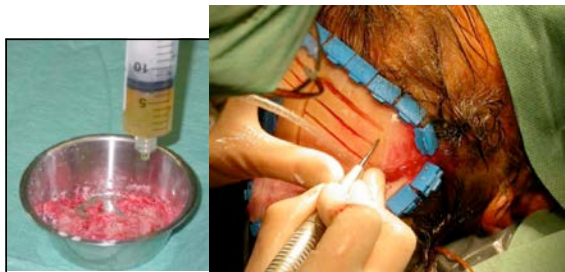
The results presented here show that PRP used in conjunction with allografts and autografts allows a very good bone quality and density for implants to be placed .

After four years of functional load, all implants are successful.

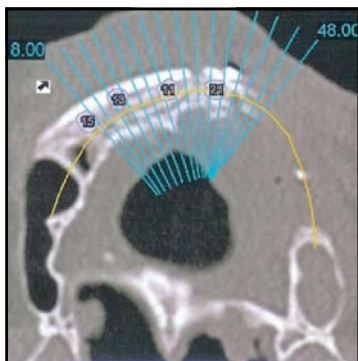
Case 1



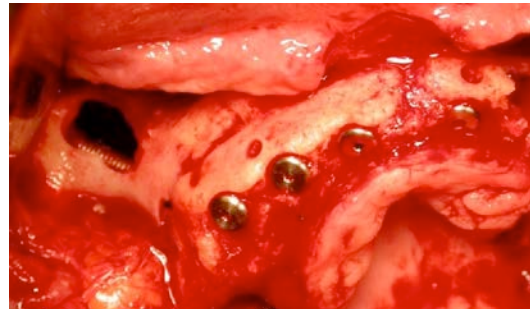
48 years-old patient, with a posttraumatic loss of the half left part of the maxilla. A CT-Scan reveals also a severe horizontal resorption of alveolar bone, because of longstanding edentulism.



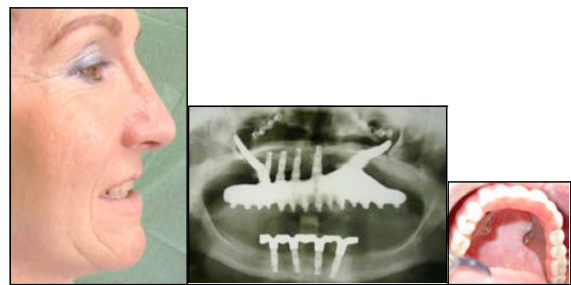
The anterior part of the maxilla is reconstructed with cranial bone, and a mixing of allograft particules and PRP.



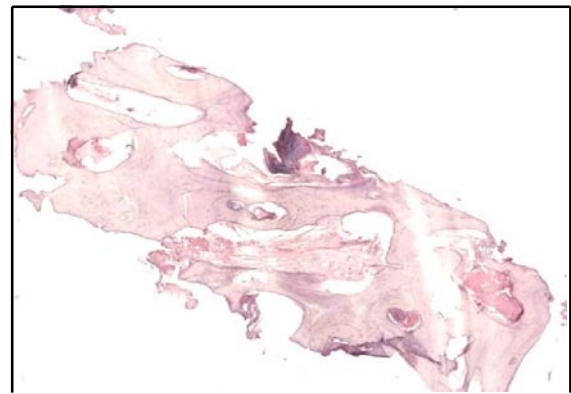
CT-Scan 5 months post surgery shows a good reconstruction, which allows the placement of 4 conventional implants.



Two zygomatic fixture are placed, as well as four conventional implants.



A fixed prosthesis on the base of a monobloc titanium frame has been constructed and screwed on the two zygomatic fixtures and the four conventional implants.



At 5 months post-reconstruction, a good bone maturation (lamellar bone present) can be observed.